1 Breastfeeding Service, Royal Women's Hospital, Parkville, Australia

2 Judith Lumley Centre, La Trobe University, Victoria, Australia

3 Raices Family Wellness Clinic, Madrid, Spain

4 Division of Breast Health & Breastfeeding Medicine, Department of Obstetrics & Gynecology, SUNY Upstate Medical University, Syracuse, NY, USA

5 Portsmouth, UK

Correspondence to L Amir
l.amir@latrobe.edu.au

Cite this as: *BMJ* 2021;374:n1628
http://dx.doi.org/10.1136/bmj.n1628
Published: 13 July 2021

PRACTICE POINTER

Identifying the cause of breast and nipple pain during lactation

Lisa H Amir,[1,2] Carmela Baeza,[3] Jayne R Charlamb,[4] Wendy Jones[5]

What you need to know

- The most frequent cause of nipple pain in breastfeeding women is poor latch or attachment to the breast
- An itchy, erythematous rash on the nipple, areola area, or breast is likely to be eczema, and should not automatically be diagnosed as nipple thrush
- Persistent nipple and breast pain during lactation is usually multifactorial. Elicit factors from maternal, infant, medical, mental, and psychosocial health, as well as from mechanical trauma or infection

A first time mother developed left nipple pain 24 hours after the birth. This persisted despite trying nipple shields and topical lanolin. On day 7 she developed mastitis in her left breast and was prescribed flucloxacillin, but the nipple and breast pain continued. Her friend suggested oral probiotics, to no effect. At the breastfeeding clinic (6 weeks postpartum) the left breast pain was excruciating and a burning pain had started in her right breast. She was also concerned about her baby's slow weight gain. On examination, her nipples were sensitive to light touch and examination of the baby indicated torticollis. When observing a feed, good positioning and attachment was seen on the right but the infant's torticollis made it difficult for him to attach on the left side and the mother quickly took him off her breast because it was too painful. The left nipple was flattened after the feed.

More than 70% of first time mothers report nipple and/or breast pain in the first week post partum.[1] This is frequently nipple pain resulting from inadequate latching; however, multiple diagnoses should be considered.[2]

This article helps clinicians promptly identify and resolve the underlying cause(s) of pain so that premature cessation of breastfeeding can be avoided and the breastfeeding relationship becomes enjoyable for mother and baby. We explain the three elements of assessment—the mother's health, the infant's health, and the dyadic interaction between the two—and hope to encourage clinicians to further their training in breastfeeding medicine. Detailed management is beyond the scope of this article but a summary table is provided, including information to guide referral.

We have used evidence from systematic reviews and large cohort studies, where available, but evidence in this field is lacking. Generally, consensus is poor on definitions and diagnoses, but we have used information from clinical guidelines, including the National Institute for Health and Care Excellence (NICE) and the Academy of Breastfeeding Medicine (ABM).[3]

How do you diagnose the cause of breast or nipple pain?

Use a respectful, individualised, family centred approach to address the mother's concerns, and to assess mother and infant separately and together (fig 1).[4 5] Formulate the likely diagnosis/diagnoses (from the causes in box 1) by obtaining a clear timeline and description of the problem.

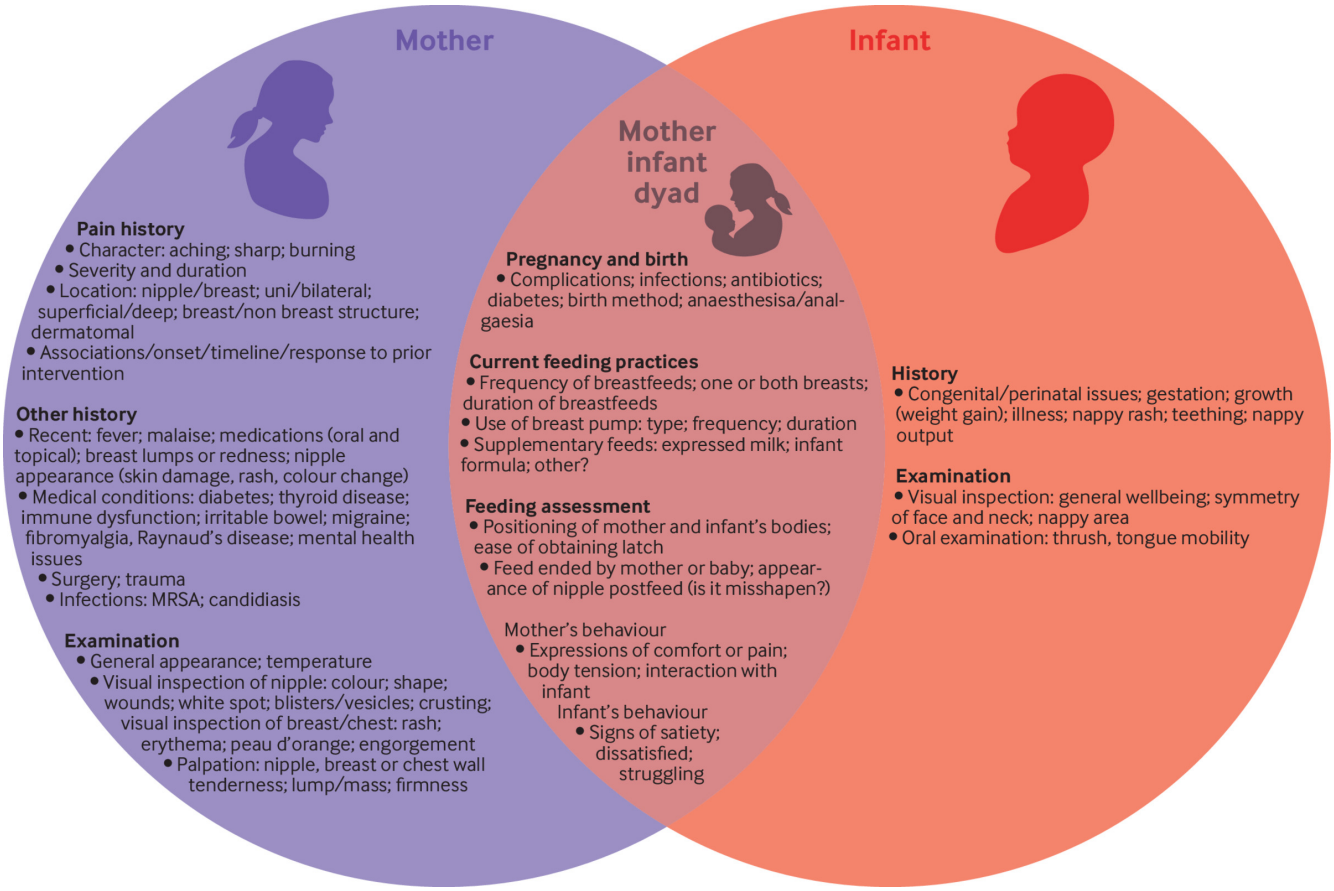

Fig 1 | Assessment of mother and baby for breast or nipple pain in the mother

Box 1: Causes of nipple and breast pain during lactation

Nipple painInadequate latch

Can cause mechanical damage to the nipple

Infant oral anatomy

For example, an asymmetric jaw or a restricted frenulum (tongue tie), or excessive intra-oral vacuum during sucking[6 7]

Poor milk expression technique

Breast pumps can cause nipple damage if the breast pump flange is too small, or if the pressure is too high or prolonged

Nipple bleb/white spot

A superficial, inflammatory fibrinous lesion, appearing as a white spot on the nipple tip which may block a nipple opening, causing mild to severe nipple pain (fig 2) (This can lead to a blocked duct[8])

Nipple vasospasm/Raynaud's

Can be a primary cause of pain. Or can be a secondary response to pain or nipple trauma (damaged nipples or thrush). Usually in individuals with poor circulation who experience cold hands/feet

Nipple dermatitis

May be atopic, irritant (from nipple creams (fig 3) or complementary foods remaining in infant's mouth) or contact dermatitis (from breast pads) or psoriasis

Bacterial nipple infection

Nipple damage that is present for >24 hours is commonly colonised with *Staphylococcus aureus* (fig 4)

Dimple nipple

Uncommon. A nipple tip which folds in on itself can lead to ongoing pain as the skin inside the fold is fragile, and may become macerated[9] (fig 5). The macerated skin fails to heal, unless the nipple tip can be kept everted after feeds

***Herpes simplex* infection**

Occurs when infection is transferred to the nipple/areola from an infected source, eg visitor with cold sore touches mother's hand and is transferred to nipple; or in later months the child may develop herpes stomatitis from contact at childcare, and transfer from mouth to nipple[10]

Causes of breast painEngorgement

Can occur at 2-10 days post partum when the milk "comes in," or if breastfeeding is stopped abruptly, or if many hours pass without removing milk from the breast[3]

Blocked (or plugged) duct

Pain usually lessens after a feed. No systemic symptoms.[11] May lead to mastitis[3] (fig 6)

Mastitis

May be non-infectious (eg, when the infant sleeps through the night for the first time), but can progress to infection, especially if nipple damage is present and bacteria can enter breast tissue (usually in first eight weeks post partum).

One in five breastfeeding women are diagnosed with mastitis,[12] and the usual organism is *S aureus*.[13] Signs and symptoms are similar to a blocked duct but women usually also have systemic illness (figs 6, 7). Breast cellulitis is a type of mastitis and may be caused by a *Streptococcus* spp infection rather than the typical *S aureus*.[14]

Breast abscess

A collection of pus within the breast tissue, usually (but not always) occurring after mastitis. Occurs in 3% of women with mastitis[15]

Breast cyst or galactocele

A fluid or milk filled cyst within the breast may present as a tender swelling/lump[11]

External trauma to breast

Vigorous massage of the breast can cause bruising, as can a bump from toddler's foot or similar hard knock

Non-lactation related skin conditions

Any skin condition can occur on the breast during lactation—eg, breast eczema (fig 8). Likewise exogenous effects like sunburn—just as they may at any other time

Conditions that can cause breast and/or nipple painThrush

Occurs when there is an overgrowth of *Candida* spp on nipple and or breast; may start on one side and spread to the other nipple/breast (not related to engorgement/mastitis). Antibiotics may have been used previously.[16] Burning nipple pain is continuous, not just during feeds; breast pain may be described as radiating. Nipple soreness may develop after months of pain free breastfeeding in women predisposed to vaginal candidiasis.[17 18] Avoid diagnosing thrush solely on the mother's description of radiating/shooting pain, ie, unless it clearly follows a course of antibiotics in a patient prone to vaginal thrush, consider all other diagnoses

Herpes zoster

May occur anywhere on the nipple/breast/chest in a dermatomal distribution. Occurs infrequently and pain may be present for several days prior to onset of rash

Breast cancer (unusual cause, doesn't usually present as pain alone)Inflammatory breast cancer

Mastitis symptoms which persist despite antibiotic treatment, especially with peau d'orange appearance. Occurs infrequently

Paget's disease of the nipple

An uncommon type of breast cancer that appears similar to eczema on the breast or nipple.[19] Occurs infrequently

What to cover in the mother's history

Take a general health and medical history and, in multiparous mothers, a previous lactation history.

- Pain could be from scarring following previous breast surgery, or dermatological conditions (eczema, psoriasis, or other skin issues)
- Autoimmune conditions such as thyroiditis, diabetes, and other autoimmune conditions can target the mammary gland.[20] Depression, fibromyalgia,[21] or other chronic pain conditions can cause exacerbated perception of breast or nipple pain that may or may not be related to breastfeeding, ie, the person may experience breast fullness as severe pain
- Vulvovaginal symptoms could be linked as there are similarities between the skin of the nipple and the vulva:

  History of recurrent vulvovaginal candidiasis might indicate nipple or breast thrush, or vulvodynia (a chronic pain condition)
- Previous lactation experiences may indicate the mother's attitude towards breastfeeding. Were they able to breastfeed for as long as they wished to previously?

  A mother who previously breastfed for more than 12 months is likely to persevere during early problems

  Did the mother have similar problems previously? Was it owing to nipple anatomy (eg, flat/inverted/dimpled nipples)?
- A sensitivity to cold (the woman might describe "poor circulation") or history of Raynaud's disease in herself or family, could suggest nipple vasospasm (Raynaud's phenomenon of the nipple) as a primary cause or contributing factor to her pain.[22]

Ask about the pain

Consider nipple and breast pain separately, although patients often use the terms interchangeably.

- What is the location of the pain? Is it in the nipple or the breast, deep versus superficial, unilateral- versus bilateral, non-breast structure (could it be chest wall or internal, eg, pleurisy?)
- If the site of the pain is indicated by a finger pointing to the sternal edge, costochondritis (inflammation of the costochondral junction) is likely[23]
- What is the character of the pain?

  Achy pain is present with the continuum of engorgement, blocked duct, and mastitis

  Other characteristics, such as shooting, burning, or needle-like pain, can indicate the source of the pain is from the breast ducts, even in a non-lactating breast.[23] This type of pain may be present in breast thrush, but is not pathognomonic of this condition. If burning nipple pain occurs only on latching or only with direct breastfeeding, the diagnosis is more likely caused by attachment difficulty
- When does the pain occur?

  If pain is continuous it could be owing to a nipple or areolar skin condition; infection; or a severely damaged nipple

  See below "Assessment of dyadic interaction" for pain during or after a feed.

Severity acknowledges the importance of mothers' discomfort and can be useful to monitor management, but does not indicate the cause of pain.

Ask about onset and associated, exacerbating, or relieving features

- Was the onset with illness (missed feed?), teething (baby feeding poorly), menses, or a new pregnancy (hormonal sensititivity)?
- Itching and rash on other areas of the body is suggestive of eczema/dermatitis
- Chills, flu-like aching, malaise, and systemic illness is suggestive of mastitis[3]
- Pain exacerbated by cold surroundings (eg, freezer section of supermarket, or being exposed to cold wind), or relieved by heat (eg, heat packs, warm shower, or even warming the breast with their hand) could indicate nipple vasospasm or Raynaud's phenomenon of the nipple
- Coexisting pain and past painful conditions can be associated with central sensitisation, which can amplify pain[24-26]
- Management history—have any remedies or treatments suggested by friends, family, social media, or other healthcare professionals helped?
- If the obstetric/postnatal history includes antibiotic use, consider nipple/breast thrush
- Oral probiotics and topical lanolin are commonly tried for pain during lactation, despite minimal evidence for their effectiveness[27 28]
- If nipple creams or pads have worsened symptoms, consider irritant or contact dermatitis (fig 2)

- If topical steroids have had no effect, consider the rare Paget's disease of the nipple[19]
- If mastitis has not responded to antibiotics in individuals with autoimmune conditions,[20] consider autoimmune mastitis (uncommon).

Fig 2 | White spot on nipple after feed

Mothers' concerns might offer clues to diagnosis/es

- She may have been assured her that breast implants would not affect breastfeeding; however, implants can be associated with pain during lactation[29]
- A common fear is that breast changes are cancer related; however, most commonly, new lumps are caused by a blocked duct, mastitis, or abscess
- If pain is ongoing, assess the psychosocial impact on the mother and the family.[5 30]

  Does the mother have adequate support (physical and emotional)?

  Does she feel conflicted, powerless, frightened, or depressed? Does anxiety or uncertainty related to pain cause resentment of the infant, the breastfeeding process, or motherhood itself? Consider asking about past or present physical or emotional abuse. These factors exacerbate symptoms for some[25]

  Breastfeeding aversion can manifest as breast or nipple pain during lactation.[31]

What to cover in the mother's examination

On inspection, how is the mother's overall appearance? If she looks unwell, consider mastitis. If she looks pale, consider anaemia (which may contribute to fatigue or exhaustion, exacerbating pain). Dry skin or signs of dermatitis may be visible on face or hands.

It is common for pain to cause worry; however, consider safety, financial, and/or mental wellbeing concerns if the mother appears overly anxious.

Visually assess both breasts and/or nipples, being aware that skin lesions may differ according to skin pigmentation.[32 33]

- Surgical scars or nipple piercing may be evident (and may cause localised pain)
- Look for nipple damage[34] and other signs that may suggest the cause of the pain (there may be none):

  Both very long nipples and poorly protractile ("flat" or inverted) nipples can be painful, if mother cannot latch baby deeply onto the breast

  Visible white spots or "nipple blebs" may be present on the nipple tip (fig 3)[8]

Eczema/dermatitis/psoriasis is usually an itchy erythematous well defined rash on the nipple or areola (fig 2). If crusty or flaky, a secondary bacterial infection may be present[35] (fig 4)

Yellow crusting or exudate could indicate bacterial infection; there will also be evidence of nipple damage and/or eczema (fig 4)

On people with darker skin tones, nipple dermatitis tends to have a brown, violaceous or grey-coloured hue—history can help with the diagnosis if examination findings are unclear (eg, history of childhood eczema or sudden onset of itchiness)[36]

Post-inflammatory hypopigmentation following areolar dermatitis can be more profound in people with darker skin tones[36]

Herpes simplex presents as extremely painful small red or fluid-filled blisters, or open sores[35]; typical presentation is mother of a toddler with herpes stomatitis with lesions where the baby's mouth comes in contact with the mother's nipple/areola[10]

An anatomical variant of the nipple where the centre is folded in, dimple nipple (fig 5) might be seen, which is a prompt to examine inside the fold for macerated skin, which can be slow to heal[9]

The nipple tip may turn white when exposed to the cold, indicating nipple vasospasm. It is more common for the vasospasm to be caused by a tendency to poor circulation[22]; however, Raynaud's disease might be causing the pain

Bleeding from the nipple is usually due to nipple damage.

- Look for breast signs (there may be none):

Bilateral fullness might indicate engorgement. Redness might indicate blocked duct/mastitis (figs 6, 7). If swelling and redness is marked, and spreading across the breast/chest, it is cellulitis. In darker skin tones, erythema may not be obvious (consider other markers[37])

Peau d'orange appearance might indicate cellulitis, or rarely inflammatory breast cancer

Well demarcated itchy erythematous lesions extending from areola onto the breast could be breast eczema; crusty appearance suggests *S aureus* colonisation (fig 8)

If breasts have been exposed to the sun, painful red appearance might be caused by sunburn.

Fig 3 | Flaky, itchy right nipple/areola dermatitis. Initially treated as thrush but worsened with miconazole gel. Baby 17 months

Fig 4 | Scab and crack on tip of nipple with yellowish crust/exudate, indicating bacterial nipple infection. Baby had black bowel motion (bleeding from nipple)

Fig 5 | Dimple nipple (damage inside the dimple). Ongoing nipple pain at 3 months

Fig 6 | Blocked duct/early mastitis: redness on left breast. Baby 3 months

Fig 7 | Mastitis in right breast. Mother 36 weeks' pregnant, with symptoms for two days

Fig 8 | Eczema lesions on lateral breast. History of eczema on hands

Palpation is not always necessary. Palpate the breast if the mother has reported "lumps," nodules, or swellings in her breast/s, or if you see any bulging area. This could indicate blocked duct, mastitis, galactocele, abscess or in very rare cases, malignancy.

With engorgement, both breasts can be tender, tense, and "full." A blocked duct or mastitis may cause localised tenderness in a section of one breast that may be swollen or hard. With mastitis, the breast might be inflamed, firm, and lumpy. Breast abscess may cause a localised, tender, and firm or fluctuant swelling or lump; but this may not be palpable if it is deep within the breast. Localised heat and tenderness are also useful indicators of mastitis, especially in darker skin tones when erythema might not be obvious.[37]

If the breast is red and tender, take the mother's temperature. ABM advises considering mastitis if the woman has a fever of 38.5°C or greater (this may be affected by recent analgesia). However, women

with a breast abscess may have no fever, ie, their temperature is likely to be less than 38.5°C.

Perform a full breast examination where a blocked duct or mastitis recurs in the same location, to exclude a persistent mass that might be suggestive of malignancy.

Take a history about the infant's health

- Birth history may reveal prematurity or other reasons for poor feeding
- Do not miss low infant weight gain by solely focusing on maternal pain; ask about growth and weight gain
- Inquire if infant tongue-tie has been suggested by other health professionals so you can address this in your examination (see "Common pitfalls" below)
- Has the infant been vomiting fresh blood or black stools? This suggests bleeding from nipple trauma but is not harmful to the infant.

What to cover in the infant examination

Asymmetric body/neck/head posture in the infant (eg, in torticollis) makes comfortable breast attachment difficult. Facial asymmetries or fractured clavicle after a traumatic birth may also cause difficulties with latching.

Assess for "classic tongue-tie." NICE defines this as when the lingual frenulum restricts tongue movement.[38] The Tongue-tie and Breastfed Babies assessment tool is helpful in determining severity of tongue tie.[39]

Look for white patches inside cheeks or lips, which are suggestive of oral thrush. However, a mother can be diagnosed with nipple thrush without any signs in her infant, and white tongue alone in an infant is usually just a "coated tongue."[40]

Assessment of suck can detect mechanical issues (suboptimal tongue movement, high palate, high or low intraoral muscle tone) which could be the cause of pain, but using this technique for diagnosis requires training.

How to assess the interaction between mother and baby

Ask about any pregnancy or birth complications that led to early separation of mother and baby, ie, disruption of postpartum skin-to-skin and early breastfeeding practices. For example, did maternal diabetes in pregnancy lead to infant hypoglycaemia and early supplementation with infant formula? Was admission to the neonatal/special care unit needed?

Ask about current feeding practices:

- How often are breastfeeds? One or both breasts? For how long?
- Are supplementary feeds given?

  With expressed breast milk, infant formula, other?

Complete assessment includes observing a breastfeed—if your time or skills are restricted, refer to a local lactation consultant/breastfeeding support for this.

- Check positioning and attachment (box 2). Awkward feeding positions involving maternal thoracic rotation and flexion may cause thoracic musculoskeletal strain[42]
- Does infant pathology (eg, fractured clavicle) or asymmetry affect latch and feeding position?

Box 2: How to assess breastfeeding positioning and attachment

- Check that the infant is being held close to the mother, facing the breast with wide open mouth so that they latch on to the breast, not the nipple[41]
- Check for awkward positions involving mother rotating and flexing her thoracic area.[42] Mother should be leaning back slightly, like on a deck chair, with her feet on the floor/supported and shoulders symmetrical and relaxed[25] (fig 9)
- Check that the mother is bringing the baby to the breast (not breast to baby), and that the baby's chin is pressing into the breast with nose free. If baby's nose is buried in the breast, bring baby's bottom in closer
- Baby's cheeks should be round (not sucked in), and jaw opens and closes as baby swallows[43]
- Initial sucks are quick until the milk lets down, and then sucking should be rhythmical

Fig 9 | Comfortable position for breastfeeding: mother leaning back and supporting baby's body with her own body. Baby's body is facing mother's body with head and neck in line with spine, one arm either side of the breast so baby's hand is in contact with breast

Assess pain during and after the feed. Pain present only at the start of a feed usually indicates nipple trauma from sub-optimal attachment, which could be related to nipple anatomy or infant anatomy. Pain after a feed could be nipple vasospasm, white spot causing blockage and local duct spasm, or breast thrush. Blocked duct pain usually lessens after a feed.

Also check for nipple colour change after a feed. If the nipple is white and malformed (flattened, creased, pointed, etc) **immediately** upon coming out of baby's mouth this is owing to compression from poor attachment. In nipple vasospasm, the nipple tip, or part of the nipple tip, turns white **shortly after** the feed and is associated with throbbing pain; mothers who hold breast in their hand may be warming the nipple to reduce pain. In classic Raynaud's phenomenon of the nipple, the nipple tip turns white, followed by blue or red and blue, ie, biphasic or triphasic colour changes.[22]

Consider primary care diagnostic tools

ABM[3] recommends milk culture when mastitis is not responding to first line antibiotics, is recurrent, bilateral, or unusual.[3]

S aureus is usually present when the nipple/areola is damaged,[2 44-46] therefore routine skin swabs are not usually done. However, consider skin swabs for persistent infection to rule out meticillin-resistant *S aureus* or an unusual organism, such as herpes simplex.[35]

Box 3 summarises common diagnostic pitfalls.

Box 3: How to avoid common diagnostic pitfalls

Misdiagnosis and missed diagnosis occurs when clinicians have little education in breastfeeding medicine. To avoid common pitfalls:

- Recognise that pain could be due to a poor latch
- Don't assume a diagnosis of nipple or breast thrush if the pain is described as burning[47 48]
- Acknowledge overdiagnosis of tongue-tie, ie, when normal oral anatomy is diagnosed as tongue-tie and released unnecessarily. Become familiar with infant oral anatomy and explain to parents that the presence of a lingual frenulum is not synonymous with "tongue-tie." Be aware that in some settings posterior tongue-tie is being diagnosed and treated on the basis of "a tight, non-visible submucosal band of tissue at the very base of the ventral tongue that is palpated rather than seen"; treatment involves invasive deep submucosal dissection which is potentially harmful, and not evidence based[49]
- Recognise there may be multiple contributing factors[35]
- Recognise that management options may be contributing to symptoms (eg, irritant dermatitis secondary to using topical nipple agent[25]; trauma from too small nipple shield or pump flange; overly vigorous breast massage)
- Assess infant growth and health as well as mother health
- Be aware of conditions where breast pain or perception of breast pain is unrelated to breastfeeding, eg, fibromyalgia,[21] musculoskeletal strain,[42] breastfeeding aversion[31]

What are the primary care management options, including referral advice?

Support parents to maintain breast milk feeding, while recognising their infant feeding plans.[50 51] Use a respectful, individualised, family centred approach to inform and support the mother and family, empowering them to make decisions suitable for their situation and cultural preferences.[5]

Refer to an infant feeding expert for prompt, immediate assistance when the woman has nipple pain after the first week or so; and if a multiparous mother has a history of early breastfeeding cessation (eg, within the first month). Further primary care management options, including referral advice, are summarised in box 4.

Box 4: Summary of primary care management and when to refer

Inadequate latch, nipple damage, poor milk expression technique, and/or nipple blanching and malformation immediately after feed

Refer to local infant feeding specialist for practical help, including finding comfortable feeding positions for mother and baby. Mother may consider expressing by hand or with a hospital grade breast pump until nipples heal

Classic tongue-tie

A simple scissor frenotomy in the early months can reduce pain if the infant frenulum is tight and impairing breastfeeding (evidence from the NICE guideline and a recent US meta-analysis).[38 52] No evidence suggests that infants need treatment for upper labial or "buccal" ties.[6 49 53]

Nipple eczema

Apply a strong steroid ointment, sparingly, to the affected area after breastfeeding, for up to 10 days (absorption by the infant should be minimal if steroid is used as directed). Avoid soap or shampoo on breasts. An emollient can be used on nipples (eg, purified lanolin). Reassure patients that post-inflammatory nipple hypopigmentation, which is not uncommon in darker skin after areolar dermatitis, is usually temporary[35 54]

Bacterial nipple infection or infected eczema

Consider topical antibiotic ointment, eg, mupirocin, if wound is not healing; or oral antibiotic if infection is spreading to the breast (ie, mastitis/cellulitis)

Nipple vasospasm/Raynaud's

Explain the condition to the mother and suggest she keep warm, avoid airing her nipples, and regularly apply heat packs to nipples/breasts. If pain persists, consider oral nifedipine

Herpes simplex/zoster infection

Consider oral antiviral treatment, unless infection is resolving. Great care should be taken to avoid any contact between the infant and open lesions. If lesions are present on the nipple or areola, the mother should be instructed to express and discard milk from that breast until the lesions have healed.

White spot/milk bleb

May resolve spontaneously. Consider de-roofing with a sterile needle if it is thin and causing an acute blockage. Case report evidence suggests that a small amount of strong steroid ointment, applied daily and covered with clingfilm wrap between feeds to increase absorption, can be effective[55]

Engorgement, blocked ducts, and mastitis

Improve breast drainage with extra feeds or expressing, application of cold packs, and oral analgesia. Mother can gently massage toward the nipple when feeding/expressing; after feeds gentle light stroking from areola toward axilla can reduce swelling.[56] Management of mastitis is similar, but antibiotics are added if symptoms persist after 24 hours, according to the ABM guidelines (based on a World Health Organization review in 2000).[3 57] Anti-staphylococcal antibiotics, such as flucloxacillin, are preferred[3] (cephalexin or clindamycin in cases of penicillin allergy)[58]

Breast abscess

If suspected, refer for ultrasonography. Abscesses can be drained by the radiologist by needle aspiration with local anaesthetic[3]

Thrush

Apply topical antifungal to the nipples after feeds, and treat the infant with an oral antifungal (eg, miconazole oral gel). Prescribe oral fluconazole to the mother if she has breast pain

Friction from using a breast pump

Try larger size flange; apply lubrication to areolae prior to pumping (olive oil or purified lanolin)

Red flags

- Breast masses that persist despite active management for longer than ~ one week (ABM protocol)[11]
- Mastitis recurring in same part of the breast
- Nipple/areolar eczema not responding to treatment (suspect Paget's disease of the nipple)[19]

Refer for diagnostic ultrasound to differentiate between fluid collections (eg, galactocele or breast abscess), and solid masses.[59] If cancer is suspected, a mammogram and/or biopsy may be required in consultation with specialists in radiology/surgery.[11] However, reassure women that acute lumps are most likely to be blocked ducts, acute mastitis, or abscess and unlikely to be cancer related

Non-red flag associated medical conditions

- Refer to rheumatology if autoimmune mastitis is suspected in patients with autoimmune conditions such as systemic lupus erythematosus[20]
- Refer to dermatology if skin condition does not resolve with usual management, and/or if infection is present[35]
- Consider physiotherapy referral for mother if tenderness in chest wall, pectoral muscles, or back suggest musculoskeletal strain[25]

- Infants with torticollis or other signs of head and neck asymmetry can be referred to a physiotherapist or osteopath experienced in paediatrics

Associated psychosocial signs or symptoms

- Consider referring first time mothers for parenting support and/or peer support
- Refer for psychosocial support if a mother needs further help with her mental wellbeing

Resources showing positioning and attachment

- Breastfeeding videos, Global Health Media. https://globalhealthmedia.org/videos/
- Breastfeeding videos, Raising Children Network. https://raisingchildren.net.au/newborns/breastfeeding-bottle-feeding/breastfeeding-videos

Education into practice

- What questions could you ask to understand the characteristics of breast or nipple pain during lactation and its likely cause?
- How do you account for different cutaneous presentations of pain in individuals with darker skin?

How patients were involved in the creation of this article

On 16 June 2020, Wendy Jones posted three questions to breastfeeding women via her Facebook page "Breastfeeding and Medications." The questions were: What do you want doctors to know about nipple pain? How does nipple pain make you feel? Does nipple pain affect the rest of your family too? Within 24 hours, she received 31, 15, and 13 responses, respectively. We incorporated these responses into the article, by stressing the importance of latching, that pumps can cause pain, that not all pain is due to thrush, and that it's OK to refer if you don't know the answer. The respondents' comments about the effect of breast/nipple pain during lactation on the whole family motivated us to include the description of family centred assessment. We will inform the public when the paper is published on Wendy's Facebook page.

How this article was made

We bring skills from working with mothers and babies in four countries, and although the healthcare systems vary, our approach is similar. We have used research and guidelines where available, but the paper mostly comes from our clinical experience. The authors are experienced in breastfeeding medicine (or support breastfeeding women requiring medications) and based this article on questions commonly asked by breastfeeding mothers, as suggested by a *BMJ* appointed breastfeeding adviser and responses from women (see "How patients were involved in the creation of this article"). We consulted Michelle Rodrigues, a dermatologist with expertise in skin of colour, to ensure accuracy about this topic. The advice given is based on our expert opinion based on clinical practice, reading, and teaching.

Contributors: LHA, CB, JC, and WJ contributed equally to this work.

Competing interests: We have read and understood the *BMJ* policy on declarations of interest and declare the following interests: none.

Provenance and peer review: commissioned; externally peer reviewed.

1 Buck ML, Amir LH, Cullinane M, Donath SMCASTLE Study Team. Nipple pain, damage, and vasospasm in the first 8 weeks postpartum. *Breastfeed Med* 2014;9:56-62. doi: 10.1089/bfm.2013.0106 pmid: 24380583

2 Kent JC, Ashton E, Hardwick CM, etal. Nipple pain in breastfeeding mothers: Incidence, causes and treatments. *Int J Environ Res Public Health* 2015;12:12247-63. doi: 10.3390/ijerph121012247 pmid: 26426034

3 Amir LHAcademy of Breastfeeding Medicine Protocol Committee. ABM clinical protocol #4: Mastitis, revised March 2014. *Breastfeed Med* 2014;9:239-43. doi: 10.1089/bfm.2014.9984 pmid: 24911394

4 Cleugh F, Langseth A. Fifteen-minute consultation on the healthy child: breast feeding. *Arch Dis Child Educ Pract Ed* 2017;102:8-13. doi: 10.1136/archdischild-2016-311456 pmid: 27469126

5 Park M, Giap TT, Lee M, Jeong H, Jeong M, Go Y. Patient- and family-centered care interventions for improving the quality of health care: A review of systematic reviews. *Int J Nurs Stud* 2018;87:69-83. doi: 10.1016/j.ijnurstu.2018.07.006 pmid: 30056169

6 LeFort Y, Evans A, Livingstone V, etal. Academy of Breastfeeding Medicine Position Statement on ankyloglossia in breastfeeding dyads. *Breastfeed Med* 2021;16:278-81. doi: 10.1089/bfm.2021.29179.ylf pmid: 33852342

7 McClellan H, Geddes D, Kent J, Garbin C, Mitoulas L, Hartmann P. Infants of mothers with persistent nipple pain exert strong sucking vacuums. *Acta Paediatr* 2008;97:1205-9. doi: 10.1111/j.1651-2227.2008.00882.x pmid: 18489617

8 Mitchell KB, Johnson HM. Breast pathology that contributes to dysfunction of human lactation: a spotlight on nipple blebs. *J Mammary Gland Biol Neoplasia* 2020;25:79-83. doi: 10.1007/s10911-020-09450-7 pmid: 32495215

9 Wilson-Clay B, Hoover K. *Flat and inverted nipples. The Breastfeeding Atlas.* LactNews Press, 2013: 44-50.

10 Amir L. Test your knowledge. Nipple pain in breastfeeding. *Aust Fam Physician* 2004;33:44-5.pmid: 14988960

11 Mitchell KB, Johnson HM, Eglash AAcademy of Breastfeeding Medicine. ABM Clinical Protocol #30: Breast masses, breast complaints, and diagnostic breast imaging in the lactating woman. *Breastfeed Med* 2019;14:208-14. doi: 10.1089/bfm.2019.29124.kjm pmid: 30892931

12 Cullinane M, Amir LH, Donath SM, etal. Determinants of mastitis in women in the CASTLE study: a cohort study. *BMC Fam Pract* 2015;16:181. doi: 10.1186/s12875-015-0396-5 pmid: 26674724

13 Rimoldi SG, Pileri P, Mazzocco MI, etal. The role of Staphylococcus aureus in mastitis : A multidisciplinary working group experience. *J Hum Lact* 2020;36:503-9. doi: 10.1177/0890334419876272 pmid: 31593644

14 Lawrence RA, Lawrence RM. *Streptococcal infections. Breastfeeding: A Guide for the Medical Profession.* Mosby, 2005: 877-9.

15 Amir LH, Forster D, McLachlan H, Lumley J. Incidence of breast abscess in lactating women: report from an Australian cohort. *BJOG* 2004;111:1378-81. doi: 10.1111/j.1471-0528.2004.00272.x pmid: 15663122

16 Dinsmoor MJ, Viloria R, Lief L, Elder S. Use of intrapartum antibiotics and the incidence of postnatal maternal and neonatal yeast infections. *Obstet Gynecol* 2005;106:19-22. doi: 10.1097/01.AOG.0000164049.12159.bd pmid: 15994612

17 Tanguay KE, McBean MR, Jain E. Nipple candidiasis among breastfeeding mothers. Case-control study of predisposing factors. *Can Fam Physician* 1994;40:1407-13.pmid: 8081120

18 Clinical Knowledge Summary. Breastfeeding Problems: Management NICE, 2017. https://cks.nice.org.uk/topics/breastfeeding-problems/

19 Cinotti E, Galluccio D, Tognetti L, etal. Nipple and areola lesions: review of dermoscopy and reflectance confocal microscopy features. *J Eur Acad Dermatol Venereol* 2019;33:1837-46. doi: 10.1111/jdv.15727 pmid: 31166040

20 Goulabchand R, Hafidi A, Van de Perre P, etal. Mastitis in autoimmune diseases: review of the literature, diagnostic pathway, and pathophysiological key players. *J Clin Med* 2020;9:958. doi: 10.3390/jcm9040958 pmid: 32235676

21 Sen M, Kilic MO, Cemeroglu O, Icen D. Can mastalgia be another somatic symptom in fibromyalgia syndrome?*Clinics (Sao Paulo)* 2015;70:733-7. doi: 10.6061/clinics/2015(11)03 pmid: 26602519

22 Di Como J, Tan S, Weaver M, Edmonson D, Gass JS. Nipple pain: Raynaud's beyond fingers and toes. *Breast J* 2020;26:2045-7. doi: 10.1111/tbj.13991. pmid: 32755067

23 Mansel RE, Hughes LE. Breast pain and nodularity. In: Hughes LE, Mansel RE, Webster DJT, eds. *Benign Disorders and Diseases of the Breast: Concepts and Clinical Management.* WB Saunders, 2000: 95-122.

24 Cooklin AR, Amir LH, Jarman J, Cullinane M, Donath SMCASTLE Study Team. Maternal physical health symptoms in the first 8 weeks postpartum among primiparous Australian women. *Birth* 2015;42:254-60. doi: 10.1111/birt.12168 pmid: 26088503

25 Amir LH, Jones LE, Buck ML. Nipple pain associated with breastfeeding: incorporating current neurophysiology into clinical reasoning. *Aust Fam Physician* 2015;44:127-32.pmid: 25770578

26 Woolf CJ. Central sensitization: implications for the diagnosis and treatment of pain. *Pain* 2011;152(Suppl):S2-15. doi: 10.1016/j.pain.2010.09.030 pmid: 20961685

27 Barker M, Adelson P, Peters MDJ, Steen M. Probiotics and human lactational mastitis: A scoping review. *Women Birth* 2020;33:e483-91. doi: 10.1016/j.wombi.2020.01.001 pmid: 32146088

28 Jackson KT, Dennis CL. Lanolin for the treatment of nipple pain in breastfeeding women: a randomized controlled trial. *Matern Child Nutr* 2017;13:e12357. doi: 10.1111/mcn.12357 pmid: 27477840

29 Marcacine KO, Abuchaim ESV, Coca KP, Abrão ACFV. Factors associated to breast implants and breastfeeding. *Rev Esc Enferm USP* 2018;52:e03363.pmid: 30328982

30 Cooklin AR, Amir LH, Nguyen CD, etalCASTLE Study Team. Physical health, breastfeeding problems and maternal mood in the early postpartum: a prospective cohort study. *Arch Womens Ment Health* 2018;21:365-74. doi: 10.1007/s00737-017-0805-y pmid: 29264646

31 Morns MA, Steel AE, Burns E, McIntyre E. Women who experience feelings of aversion while breastfeeding: A meta-ethnographic review. *Women Birth* 2021;34:128-35. doi: 10.1016/j.wombi.2020.02.013 pmid: 32089458

32 Taylor SC. Skin of color: biology, structure, function, and implications for dermatologic disease. *J Am Acad Dermatol* 2002;46(Suppl Understanding):S41-62. doi: 10.1067/mjd.2002.120790 pmid: 11807469

33 Mukwende M, Tamony P, Turner M. *Mind the Gap: A Handbook of Clinical Signs in Black and Brown Skin*. University of London, 2020, https://www.blackandbrownskin.co.uk/mindthegap.

34 Coca KP, Amir LH, Alves MDRDS, Barbieri M, Marcacine KO, de Vilhena Abrão ACF. Measurement tools and intensity of nipple pain among women with or without damaged nipples: A quantitative systematic review. *J Adv Nurs* 2019;75:1162-72. doi: 10.1111/jan.13908 pmid: 30407654

35 Heller MM, Fullerton-Stone H, Murase JE. Caring for new mothers: diagnosis, management and treatment of nipple dermatitis in breastfeeding mothers. *Int J Dermatol* 2012;51:1149-61. doi: 10.1111/j.1365-4632.2011.05445.x pmid: 22994661

36 Eichenfield LF, Stein Gold LF. Practical strategies for the diagnosis and assessment of atopic dermatitis. *Semin Cutan Med Surg* 2017;36(Suppl 2):S36-8. doi: 10.12788/j.sder.2017.009 pmid: 28654708

37 Kundu RV, Patterson S. Dermatologic conditions in skin of color: part I. Special considerations for common skin disorders. *Am Fam Physician* 2013;87:850-6.pmid: 23939567

38 National Institute for Health and Care Excellence. Division of ankyloglossia (tongue-tie) for breastfeeding 2005. https://www.nice.org.uk/guidance/ipg149

39 Ingram J, Copeland M, Johnson D, Emond A. The development and evaluation of a picture tongue assessment tool for tongue-tie in breastfed babies (TABBY). *Int Breastfeed J* 2019;14:31. doi: 10.1186/s13006-019-0224-y pmid: 31346346

40 Division of Oral Medicine and Dentistry, Brigham and Women's Hospital, Boston. Coated/Hairy Tongue 2016. https://www.brighamandwomens.org/assets/BWH/surgery/oral-medicine-and-dentistry/pdfs/coated-hairy-tongue-bwh.pdf.

41 Amir LH. Managing common breastfeeding problems in the community. *BMJ* 2014;348:g2954. doi: 10.1136/bmj.g2954 pmid: 24821712

42 Charette C, Théroux L. Musculoskeletal impairment: Causes of pain with breastfeeding insight into 11 cases. *Breastfeed Med* 2019;14:603-8. doi: 10.1089/bfm.2019.0047 pmid: 31314578

43 UNICEF UK. NHS. Off to the best start: important information about feeding your baby 2015. https://www.unicef.org.uk/babyfriendly/wp-content/uploads/sites/2/2010/11/otbs_leaflet.pdf.

44 Livingstone VH, Willis CE, Berkowitz J. *Staphylococcus aureus* and sore nipples. *Can Fam Physician* 1996;42:654-9.pmid: 8653033

45 Graves S, Wright W, Harman R, Bailey S. Painful nipples in nursing mothers: fungal or staphylococcal? A preliminary study. *Aust Fam Physician* 2003;32:570-1.pmid: 12901218

46 Witt A, Mason MJ, Burgess K, Flocke S, Zyzanski S. A case control study of bacterial species and colony count in milk of breastfeeding women with chronic pain. *Breastfeed Med* 2014;9:29-34. doi: 10.1089/bfm.2013.0012 pmid: 23789831

47 Amir LH, Donath SM, Garland SM, etal. Does Candida and/or Staphylococcus play a role in nipple and breast pain in lactation? A cohort study in Melbourne, Australia. *BMJ Open* 2013;3:e002351. doi: 10.1136/bmjopen-2012-002351 pmid: 23474794

48 Buck ML, Amir LH, Donath SM. Topical treatments used by breastfeeding women to treat sore and damaged nipples. *Clin Lat* 2015;6:16-23doi: 10.1891/2158-0782.6.1.16.

49 Fraser L, Benzie S, Montgomery J. Posterior tongue tie and lip tie: a lucrative private industry where the evidence is uncertain. *BMJ* 2020;371:m3928. doi: 10.1136/bmj.m3928 pmid: 33243759

50 Hoddinott P, Craig LC, Britten J, McInnes RM. A serial qualitative interview study of infant feeding experiences: idealism meets realism. *BMJ Open* 2012;2:e000504. doi: 10.1136/bmjopen-2011-000504 pmid: 22422915

51 Rollins NC, Bhandari N, Hajeebhoy N, etalLancet Breastfeeding Series Group. Why invest, and what it will take to improve breastfeeding practices?*Lancet* 2016;387:491-504. doi: 10.1016/S0140-6736(15)01044-2 pmid: 26869576

52 Shekher R, Lin L, Zhang R, etal. How to treat a tongue-tie: An evidence-based algorithm of care. *Plast Reconstr Surg Glob Open* 2021;9:e3336. doi: 10.1097/GOX.0000000000003336 pmid: 33564576

53 Australian Dental Association. Ankyloglossia and oral frena consensus statement, 2020. Australian Dental Association. https://www.ada.org.au/Dental-Professionals/Publications/Ankyloglossia-Statement/Ankyloglossia-and-Oral-Frena-Consensus-Statement_J.aspx

54 Vachiramon V, Thadanipon K. Postinflammatory hypopigmentation. *Clin Exp Dermatol* 2011;36:708-14. doi: 10.1111/j.1365-2230.2011.04088.x pmid: 21671990

55 O'Hara M-A. Bleb histology reveals inflammatory infiltrate that regresses with topical steroids; A case series. *Breastfeed Med* 2012;7(Suppl 1):S2.

56 Witt AM, Bolman M, Kredit S, etal. Therapeutic breast massage in lactation for the management of engorgement, plugged ducts, and mastitis. *J Hum Lact* 2016;32:123-31.

57 World Health Organization. Mastitis: Causes and Management. Geneva: WHO/FCH/ CAH/00.13 2000.

58 Royal Women's Hospital. Mastitis and breast abscess clinical practice guideline. 2019. https://www.thewomens.org.au/images/uploads/downloadable-records/clinical-guidelines/infant-feeding-mastitis-and-breast-abscess_220719.pdf.

59 Faguy K. Breast disorders in pregnant and lactating women. *Radiol Technol* 2015;86:419M-38M.pmid: 25835417